

Plasticity and functional recovery in neurology

VS Ramachandran



This article is based on the Oliver-Sharpey Lecture given at the Royal College of Physicians on 15 September 2004 by VS Ramachandran MD, Director, Center for Brain and Cognition, University of California, USA

Clin Med
2005;5:368-73

ABSTRACT – Experiments on patients with phantom limbs suggest that neural connections in the adult human brain are much more malleable than previously assumed. Three weeks after amputation of an arm, sensations from the ipsilateral face are referred to the phantom; this effect is caused by the sensory input from the face skin ‘invading’ and activating deafferented hand zones in the cortex and thalamus. Many phantom arms are ‘paralysed’ in a painful position. If a mirror is propped vertically in the sagittal plane and the patient looks at the reflection of his/her normal hand, this reflection appears superimposed on the ‘felt’ position of the phantom. Remarkably, if the real arm is moved, the phantom is felt to move as well and this sometimes relieves the painful cramps in the phantom. Mirror visual feedback (MVF) has shown promising results with chronic regional pain syndrome and hemiparesis following stroke. These results suggest two reasons for a paradigm shift in neurorehabilitation. First, there appears to be tremendous latent plasticity even in the adult brain. Second, the brain should be thought of, not as a hierarchy of organised autonomous modules, each of which delivers its output to the next level, but as a set of complex interacting networks that are in a state of dynamic equilibrium with the brain’s environment. Both principles can be potentially exploited in a clinical context to facilitate recovery of function.

KEY WORDS: caloric, complex regional pain syndrome, mirror feedback, phantom limbs, phantoms, somatosensory plasticity, stroke rehabilitation, vestibular

An enduring dogma in neurology for more than a century has been the notion that connections in the brain are laid down mainly in fetal life and infancy, and no new connections can be formed in the adult. This lack of ‘plasticity’ in the adult brain was held responsible for the low level of recovery of function after damage to the nervous system.

Experiments on monkeys and humans have generated a paradigm shift away from this view during the past decade. Not only is there a surprising amount of residual plasticity in the adult brain, but sensory inputs from one sense can quite literally substitute

for another sense. To overstate the case somewhat, it is as if a blind man’s cane does not merely act by allowing the man to infer obstacles using touch alone, but that the ‘visual’ centres in his brain have been ‘taken over’ by touch. The findings are not only of potential clinical importance but challenge long-held theoretical assumptions about sensory function, such as ‘Muller’s law of specific nerve energies’ (a given neuron in the brain can signal only a particular sensation) or ‘place coding’ (the experience evoked depends exclusively on the *location* of the excited neuron, not on the pattern of firing or the context in which it fires).

Many researchers have contributed to this renaissance of interest in plasticity and its clinical applications. Following the early work of Patrick Wall,¹ experiments on the somatosensory cortex of monkeys^{2,3} showed that there is a tremendous latent plasticity in the adult primate brain. For example, after dorsal rhizotomy of one upper limb, the sensory input from the ipsilateral face starts activating the deafferented ‘hand region’ of the adjacent S1 cortex.³ The finding by this author that such changes in topography occur also in human patients with phantom limbs has had striking perceptual consequences.⁴⁻⁹ Furthermore, phantom arms that are ‘paralysed’ or ‘frozen’ in an awkward, sometimes painful, position can often be reanimated by the simple device of using visual feedback to convey the illusion that the phantom is moving in response to the brain’s command.

Phantom limbs

Phantom limbs have been known about since antiquity.^{7,8} The term was originally coined by Silas Weir-Mitchell in 1872. Since then, an extensive clinical literature has emerged on the topic. However, a systematic scientific study of phantom limbs began only a decade ago, inspired mainly by the demonstration of striking changes in somatosensory maps in animals following denervation or amputation. These animal studies, combined with brain imaging and systematic psychophysical testing in amputees, has moved the study of phantom limbs from an era of vague clinical phenomenology to that of experimental research.⁷

The ‘vividness’ of the phantom is enhanced by the presence of referred sensations, ie stimuli applied to

other parts of the body that are experienced as arising from the phantom. For example, after the amputation of an arm, touching the face will often evoke precisely localised sensations in the phantom fingers, hand and arm. The points that evoke such sensations are topographically organised and the referral is modality specific: ice on the face will elicit cold in the phantom digits and vibration is felt as vibration (Fig 1). Even water trickling down the face is sometimes felt as water trickling along the phantom arm. These referred sensations probably arise because there is a complete map of the skin surface on the somatosensory cortex (S1 in the postcentral gyrus). On this map, the face abuts the hand. The sensory input from the face skin ordinarily activates only the face area of the cortex, but if the adjacent hand cortex is denervated, then the input from the face skin starts 'invading' and activating the original hand area of the cortex as well – a striking demonstration of plasticity in the adult human brain. Intriguingly, even though the hand area is now being activated by face skin, higher brain centres continue to interpret the signals as arising from the missing hand.^{4,7} The changes that occur in somatosensory cortex topography over distances of 2-3 cm have also been demonstrated in these patients using func-

tional brain imaging techniques, allowing researchers to correlate perceptual phenomena such as referred sensations with anatomy. Referred sensations also occur after the trigeminal nerve, which supplies the face, is cut: such patients then have a map of the face on the hand. Also, after leg amputation, stimuli are referred from the genitals to the phantom foot, which is consistent with position of the foot next to the genitals in Penfield's original maps.

'Paralysed' phantom limbs

Many patients claim to be able to 'move' their phantoms voluntarily but others experience the phantom as 'paralysed' in a painfully awkward position. Patients in the latter group often have a pre-existing peripheral nerve injury, such as a brachial avulsion before the amputation; ie their arm was intact but paralysed. Later, when the arm is amputated, the sense of 'paralysis' is carried over into the phantom.

How can a phantom be paralysed? Consider what happens when a person commands his/her arm to move. Corollary discharges from the motor command centres are sent in parallel to the cerebellum and parietal lobes. These structures also receive feedback 'confirmation' that the command is being obeyed from both visual and proprioceptive cues. These feed-forward and feedback signals are monitored by parietal lobes to create a vibrant dynamic internal image of the body – a person's 'body image'. If the arm is amputated, the feed-forward commands presumably continue to be monitored and are experienced as movements referred to the phantom. Now, consider the case where the arm is intact but paralysed by peripheral nerve injury. Commands are now sent out to the limb but the visual and proprioceptive feedback *fails* to confirm that they have been obeyed. The repeated feedback 'no it is not moving', is somehow wired into the circuitry of the parietal lobes – a form of 'learned paralysis'. So, if the arm is amputated, this learned paralysis is carried over into the phantom.

Is it possible to 'unlearn' this learned paralysis? What if visual feedback is resurrected so that the patient's brain once again receives confirmation that the commands are being obeyed? This can be achieved with a mirror (Fig 2).

Mirror visual feedback (MVF)

Nine arm amputees were studied.^{6,7} A tall mirror was placed vertically on the table, perpendicular to the patient's chest so that s/he could see the reflection of his/her normal hand 'superimposed' on the phantom (see Fig 2). In the first seven patients, when the normal hand was moved so that the phantom was visually perceived to move in the mirror, it was also 'felt' to move, ie a vivid kinaesthetic sensation emerged.^{6,7} These sensations could not be evoked with the eyes closed. Kinaesthetic sensations were evoked in one patient (DS) who had never experienced movements in the phantom over the preceding 10 years. Also, repeated use of the mirror for three weeks (10 min/day) resulted in a permanent 'telescoping' of the hand in this patient.

In six patients (excluding DS), a similar revival of movements

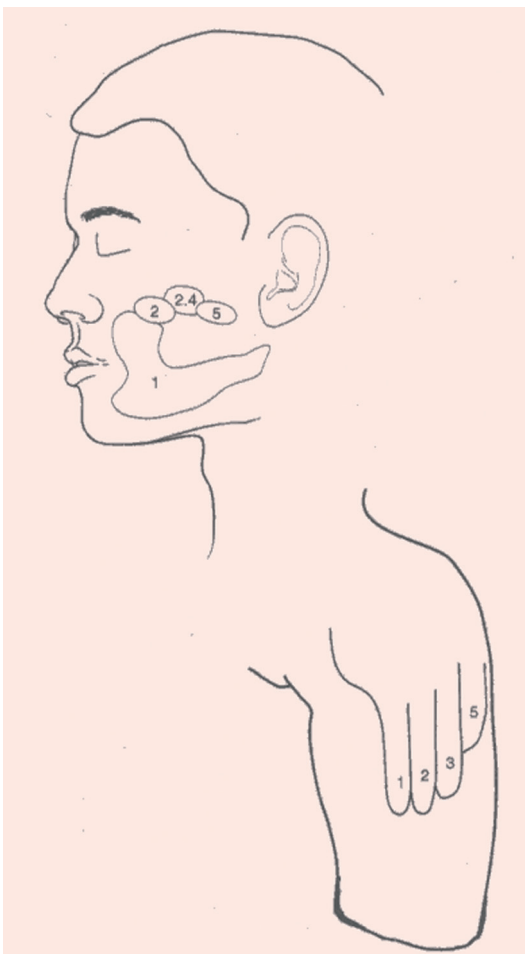


Fig 1. Touching specific areas on the face of a person with an amputated arm will often evoke precisely localised sensations in the fingers.

Fig 2. Mirror visual feedback (MVF) in a patient with an amputated left arm.



in the phantom occurred if the experimenter's hand was substituted for the patient's normal hand. Such effects were not seen in four control subjects given identical instructions.

Five patients experienced painful involuntary 'clenching spasms' of the phantom hand – 'as though the nails were digging in the phantom'.

Remarkably, in four of these patients, the spasms, which normally lasted for 1 hour or longer, could be relieved immediately upon looking into the mirror and opening both hands simultaneously. None of the eyes-closed trials was effective in relieving spasms. When motor commands are sent from the premotor and motor cortex to clench the hand, they are normally damped

Key Points

After arm amputation there is a massive reorganization of sensory maps in the human brain

In arm amputees, touch, cold, warmth and vibration applied to the ipsilateral face is referred in a modality specific manner to the phantom hand

A phantom arm that has long been 'paralysed' can be re-animating by the simple device of looking at the reflection of the moving normal arm in a sagittally placed mirror (mirror visual feedback (MVF))

MVF seems to partially alleviate phantom pain in some patients and has also been found to be useful in treating hemiparesis following stroke and in complex regional pain syndrome type 1

Vestibular/caloric stimulation may also prove to be useful in treating chronic regional pain and indeed other types of chronic pain especially if we regard pain as the right hemisphere's reaction to discrepancies in sensory input

by error feedback from proprioception. In a phantom, such damping is not possible and thus the motor output is amplified even further; this outflow itself may be experienced as a painful spasm. Visual feedback from the mirror may act by interrupting this 'loop'.

The elimination of spasms was unequivocal in all four patients. Interestingly, the associated pain also disappeared. Given the notorious susceptibility of pain to 'placebo', however, these experiments would have to have been double-blind to determine if the effect on pain is a *specific* consequence of the visual feedback.

These observations, the 'map' on the face and the mobilisation of phantoms (and, as noted below, arms 'paralysed' by stroke) using mirrors, all suggest that there is tremendous latent plasticity in the adult brain. It needs to be explored whether or not these procedures are practical in a clinical setting.^{13,14} However, the general principle has been established that input from an intact sensory system can be used to access and recruit dormant neural circuits in other brain regions, and has led to a whole new approach to neurorehabilitation.

Eliminating complex regional pain type 1 using mirrors

Complex regional pain type 1, also known as reflex sympathetic dystrophy (RSD) or Sudek's atrophy, is one of the most enigmatic disorders in rehabilitation medicine. It provides a valuable testing ground for theories of mind-body medicine.

Almost nothing is known about the pathogenesis of RSD; theories range from the claim that it is an entirely psychogenic condition to 'peripheral' theories that impute flawed sympathetic vasomotor control. Following a minor injury to a limb there is usually temporary pain and immobilisation, but in RSD the limb becomes permanently paralysed and excruciatingly

painful, grossly out of proportion to the inciting event. This has proved notoriously resistant to most available treatments, although sympathetic ganglion blocks can be helpful in some cases.

The disorder is best approached from an evolutionary standpoint. Although pain is thought of as one sensation, there are at least two types, acute and chronic, which serve fundamentally different evolutionary goals. Acute pain alerts a person to a potential danger (eg a flame) and *mobilises* his/her limb reflexly to avoid the danger. Chronic pain serves the opposite function; it serves to *immobilise* the limb to avoid tissue injury (eg in a fracture) and promote rest and recovery. Ordinarily, when the inflammation subsides, the pain resolves and mobility returns. However, this ordinarily adaptive mechanism can backfire if a Hebbian associative link (ie the tendency for neurons that fire simultaneously to get 'wired up' together) is established in the brain between the motor commands and the constantly associated pain signals that ensue. In time, the very *attempt* to move will evoke pain; this can be viewed as a form of 'learned pain'. This theory is consistent with the ingenious speculation of Harris¹⁵ that pain usually emerges from sensing *discordant* inputs, and the brain 'gives up' trying to move.

If this theory is correct, could the 'learned pain' be corrected with MVF? If each time the subject tried to move his/her dystrophic arm, s/he received visual feedback (from the mirror) that 'tricked' him/her into thinking the arm was moving and was not painful after all, would s/he 'unlearn' the learned pain and obtain relief from paralysis and pain?¹⁶ This theory was tested by McCabe *et al.*¹⁷ who tried to 'correct' this spurious 'learned pain' association in patients with RSD using MVF. About half the patients obtained instant relief from pain and immobilisation, and the temperature of the affected limb also changed as soon as MVF was used. A placebo plexiglass control was used for comparison and had no effect. The patients in whom MVF was ineffective had long-standing (several years) RSD.

Caloric vestibular stimulation

The extreme malleability of phantom limbs revealed by the above mirror studies raises the question of whether other procedures that influence body image can also influence the phantom. For example, caloric vestibular stimulation in patients with somatoparaphrenia (denial of ownership of the left arm seen in right parietal stroke) produces a dramatic, albeit temporary, recovery from denial; the patient suddenly starts acknowledging his/her arm.^{10,18} Can caloric vestibular stimulation also affect phantoms?

In one of the author's patients, a phantom arm that had endured for 11 years and associated pain vanished immediately after left-ear cold-water caloric stimulation, a finding consistent with recent work by Andre *et al.*¹⁹ Additionally, sensations were no longer referred from the face to the phantom – the map had vanished. The phantom and referred sensations returned 5–10 min after the caloric nystagmus wore off, but it remains untested whether repeated use of caloric irrigation can provide more permanent relief.

This author and others are exploring the possibility that caloric vestibular stimulation might also help patients with RSD and perhaps other 'body image' disorders, such as apotemnophilia (a rare neuropsychiatric disorder in which a patient incessantly seeks amputation of a normal limb).

Stroke

Could the above principles apply, at least to some extent, to stroke rehabilitation? The hemiparesis in stroke is the result of damage to the efferent pyramidal fibres in the internal capsule, but in the first few days after a stroke, oedema and diaschisis may contribute to the paralysis. Is it conceivable that during this period the negative feedback from the paralysed limb leads to a form of learned paralysis analogous to that seen in the phantom, so that despite resolution of the swelling the paralysis remains? If so, could a simple procedure, such as the use of MVF, help accelerate motor recovery, at least in some patients? Such a procedure would differ radically from current management,²⁰ which *restricts* use of the good arm and encourages a patient to use his/her paretic arm. In the procedure based on the assumption that at least some component of the paralysis is 'learned', a mirror is propped up vertically and the patient is encouraged to use *both* arms while receiving MVF. A pilot study of this procedure has yielded promising results.²¹

Visual feedback may also aid the recovery of a paralysed limb by tapping into polymodal neurons that exist in the primate, including human, brain. The nervous system is generally thought of as consisting of afferents, efferents and associative or internuncial neurons, a legacy that is owed to Sherrington. Yet Sherrington himself made the following observation: monkeys who undergo dorsal rhizotomy can no longer use their arm – the arm is paralysed despite the dogma that only *sensory* nerves are severed by the rhizotomy. Although the nervous system tends to be viewed as having distinct sensory and motor pathways, the entire sensory-motor loop needs to be intact for its proper function.

Spurred by Sherrington's finding and by observations on phantoms, Sathian *et al.*²² explored the possibility of using MVF in a stroke patient in whom the apparent 'paralysis' was mainly a result of massive deafferentation; the motor pathways were intact. Six months post stroke the patient was given MVF for 2 weeks and there was a striking recovery of grip strength and other useful movements (eg opening a lock) in the paretic arm.

These results^{21,22} suggest that, at least in a subset of patients, perhaps those in whom deafferentation is the main cause of the 'paralysis', MVF may accelerate recovery of function by allowing access to multimodal circuits in parietal and frontal lobes.

Intersensory plasticity

Another example of intersensory plasticity was observed in a patient who completely lost his sight as a result of progressive loss of retinal function due to retinitis pigmentosa. When asked to close his eyes in a dark room (to eliminate all stray light) and to move his hand in front of his face, slightly off to one side of fixation, he reported literally seeing (not merely feeling) his

hand moving! Psychophysical experiments to determine thresholds ruled out confabulation.²³ Functional magnetic resonance imaging of the brain revealed activity in the *visual* motion sensing area when the patient moved his hand. This suggests that 'back projections' from the somatosensory cortex become hyperactive and may feed back all the way into the visual centres after visual deprivation. It is unlikely that these effects are confabulatory, since the moving hand (in darkness) was 'seen' visually only outside the fovea and never in central vision, which is consistent with the fact that the deafferentation affected the patient's peripheral vision much earlier than his central vision. It is possible that parietal 'polymodal' cells that have both tactile and visual receptive fields might be involved in mediating these effects. If so, the findings have obvious relevance to sensory substitution in neurorehabilitation.

Conclusion

Theories on brain function over the past three centuries have been based on two extreme views. The first was the doctrine of modularity: the notion that different mental capacities, whether as mundane as motion perception or as complex as moral judgement, are mediated by relatively autonomous, highly specialised brain regions. At the other end of the spectrum is the 'holistic' view championed by Karl Lashley and revived in recent years by neural network aficionados. Work in the past decade argues against both extreme views, and instead suggests that specialised mechanisms do indeed exist but with a great deal of back and forth interaction between them; these interactions can be fruitfully exploited in neurorehabilitation.

The example of Wernicke's aphasia is interesting – these patients are completely aphasic, even for single words, and cannot comprehend the simplest utterances because of selective damage to Wernicke's area in the left temporal lobe. In contrast, studies in which words or sentences are presented to the left hemifield of a commissurotomy (split brain) patient have shown that the right hemisphere on its own can comprehend simple semantics. Why cannot the patient with Wernicke's aphasia similarly use his/her intact right hemisphere to comprehend written or spoken commands? It is almost as if the damaged Wernicke's area in the left hemisphere creates a functional derangement in the corresponding mirror loci in the right hemisphere. If so, would a commissurotomy improve comprehension in a Wernicke's aphasic?

A more familiar example is visual hemineglect caused by damage to the right parietal lobe. Every medical student knows that even though the loss is profound, it is almost always temporary, with the patient recovering completely in a few days or weeks. How could the 'lesion equals permanent deficit' model of the brain account for such a striking recovery?

Hamilton and Pasqua-Leone²⁴ recently reported that if you simply blindfold normal adults for a day, sensory input from the skin starts to activate what are conventionally regarded as 'visual' areas of the cortex!

These results,^{24,25} together with the work on MVF and caloric stimulation, suggest two things. First, there is a tremendous

latent plasticity even in the adult brain. Second, the brain should be thought of, not as a hierarchy of organised autonomous modules, each of which delivers its output to the next level, but as a set of complex interacting networks that are in a state of dynamic equilibrium with the brain's environment. The past decade of research has shown that both principles can be exploited in a clinical context to facilitate recovery of function.

Acknowledgement

The author thanks the late Francis Crick for discussion.

References

- 1 Wall P. The presence of ineffective synapses and the circumstances which unmask them. *Phil Trans Roy Soc Lond B* 1971;278:361–72.
- 2 Merzenich MM, Nelson RJ, Stryker MS, Cynader MS *et al*. Somatosensory cortical map changes following digit amputation in adult monkeys. *J Comp Neurol* 1984;224:591–605.
- 3 Pons TP, Preston E, Garraghty AK, Ommaya AK *et al*. Massive cortical reorganization after sensory deafferentation in adult macaques. *Science* 1991;252:1857–60.
- 4 Ramachandran VS, Rogers-Ramachandran D, Stewart M. Perceptual correlates of massive cortical reorganization. *Science* 1992;258:1159–60.
- 5 Ramachandran VS, Rogers-Ramachandran D. Touching the phantom limb. *Nature* 1995;377:489–90.
- 6 Ramachandran VS, Rogers-Ramachandran D. Synaesthesia in phantom limbs induced with mirrors. *Proc Roy Soc Lond* 1996;263:377–86.
- 7 Ramachandran VS, Hirstein W. The D O Hebb lecture: Perception of phantom limbs. *Brain* 1998;121:1603–30.
- 8 Ramachandran VS. *The 2003 Reith Lectures: The emerging mind*. London: Profile Books, 2003.
- 9 Ramachandran VS, Blakeslee S. *Phantoms in the brain*. New York: William Morrow, 1998.
- 10 Melzack R. Phantom limbs. *Sci Am* 1991;266:120–6.
- 11 Yang T, Gallen C, Bloom F, Ramachandran VS, Cobb S. Sensory maps in the human brain. *Nature Lond* 1994;368:592–3.
- 12 Yang T, Galen C, Ramachandran VS. Noninvasive detection of cerebral plasticity in the adult human somatosensory cortex. *Neuroreport* 1994; 5:701–4.
- 13 MacLachlan M, MacDonald D, Waloch J. Mirror treatment of lower limb phantom pain. *Disabil Rehabil* 2004;26:901–4.
- 14 Brodie EE, Whyte A, Waller B. Increased motor control of phantom leg in humans results from visual feedback of a virtual leg. *Neurosci Lett* 2003;341:167–9.
- 15 Harris AJ. Cortical origin of pathological pain. *Lancet* 1999;354:1464–6.
- 16 Ramachandran VS. Decade of the Brain Symposium. University of California at San Diego, 1998.
- 17 McCabe CS, Haigh RC, Ring EFR, Halligan PW *et al*. A controlled study of the utility of mirror visual feedback in the treatment of complex regional pain syndrome (type 1). *Rheumatology* 2003;42:97–101.
- 18 Cappa S, Strezi R, Vallar G. Remission of hemineglect and anosognosia during vestibular stimulation. *Neuropsychologia* 1987;55:775–82.
- 19 Andre JM, Martinet N, Paysant J, Beiss JM, LeCahpelin L. Temporary phantom limbs evoked by vestibular caloric stimulation in amputees. *Neuropsychiatry Neuropsychol Behav Neurol* 2001;14:190–6.
- 20 Taub E, Uswatte G. Use dependent cortical reorganization after brain injury. *Stroke* 1999;30:586–92.
- 21 Altschuler E, Wisdom S, Stone L, Foster C, Ramachandran VS. Rehabilitation of hemiparesis after stroke with a mirror. *Lancet* 1999;353:2035–6.
- 22 Sathian K, Greenspan AI, Wolf SL. Doing it with mirrors; a case study of a novel approach to rehabilitation. *Neurorehabil Neural Repair* 2000;14:73.

- 23 Ramachandran VS, Azoulay S. Psychonomic abstract. Annual meeting of the Psychonomics Society USA (abstracts).
- 24 Hamilton R, Pasquale-Leone A. Cortical plasticity. *Neuroreport* 2002; 13:571-4.
- 25 Bach Y, Rita P, Collins CC, Saunders F, White B. Visual substitution by tactile projection. *Nature* 1969;21:963-4.